


**PRESENTING CLINICAL SIGNS**

**DATE** History: Presented on 7/29 for vomiting and decreased appetite. Treated with Cerenia and SQ fluids. Sent home but returned today for open mouth breathing, panting, and frequent trips to the litter box. Muffled lung sounds, no murmur.

8/2/22

**ECHOCARDIOGRAPHIC FINDINGS**

2D, M-mode, and Doppler study.

**PERFORMED BY:**

Amanda Lacey-Crook,  
SDEP

Left atrial size is normal. The mitral valve is normal. Left ventricular wall thickness is normal. Left ventricular internal dimensions are normal. Left ventricular systolic function is hyperdynamic. The aorta and aortic valve are normal. Right atrial and right ventricular dimensions are normal. The tricuspid valve is normal. The pulmonary artery and pulmonic valve are normal. No shunting lesions are visualized. No heartworms are visualized. No pericardial effusion or cardiac masses are seen.

**INTERPRETED BY**

Keith Blass, DVM,  
MS, DACVIM  
(Cardiology)

LA/Ao - 1.46  
IVSd - 4.9 mm  
LVPWd - 4.3 mm  
LVIDd - 17.6 mm  
LVIDs - 6.0 mm  
FS - 65.9%  
RA - 10.5 mm  
LVOT - 1.19 m/s  
RVOT - 0.65 m/s

**PATIENT**

Loki Koppuzha

**SPECIES**

Feline

**ASSESSMENT/RECOMMENDATIONS**

Normal echocardiogram

**BREED**

This examination demonstrates no evidence of structural heart disease. As such, no reason for Loki's open mouth breathing is appreciated in the image set.

**DSH**

No therapy is recommended based on this exam.

**SEX**

A recheck echocardiogram is recommended if new physical exam and/or clinical abnormalities suggestive of cardiac dysfunction develop.

**MN**
**AGE**

9 y

**WEIGHT**

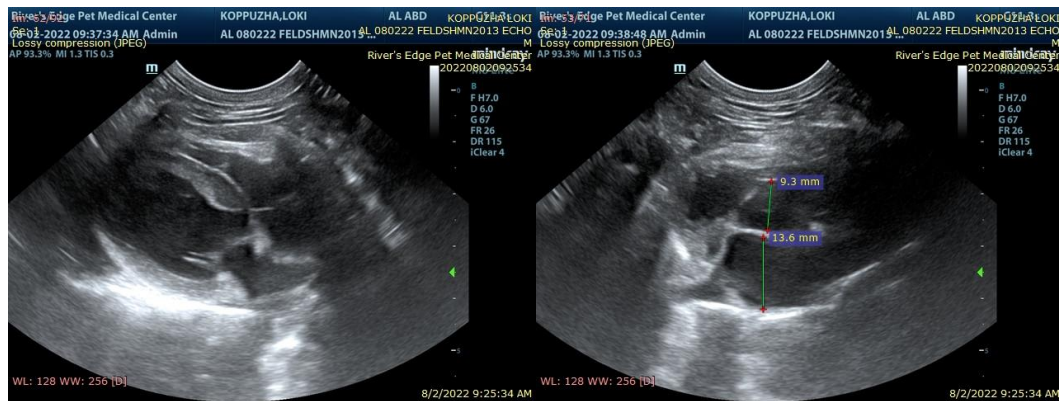
13.6 lb

**HOSPITAL NAME**

Rivers Edge PMC

**REFERRING VET**

Dr. Gray



The information and recommendations provided are based on the images presented by the referring veterinarian. No evaluation can be communicated regarding pathology that was not visible in the image/video clips provided.



**DATE**

Thank you for this referral. If the clinical or image interpretation does not parallel your findings or if I can be of any further assistance please contact me.

8/2/22

**PERFORMED BY:**

**Keith Blass, DVM, MS, DACVIM (Cardiology)**

KeithBlass@gmail.com

631-804-5754

Amanda Lacey-Crook,  
SDEP

**INTERPRETED BY**

Keith Blass, DVM,  
MS, DACVIM  
(Cardiology)

**PATIENT**

Loki Koppuzha

**SPECIES**

Feline

**BREED**

DSH

**SEX**

MN

**AGE**

9 y

**WEIGHT**

13.6 lb

**HOSPITAL NAME**

Rivers Edge PMC

**REFERRING VET**

Dr. Gray